



## Endoscopic third ventriculostomy in hydrocephalus secondary to vestibular schwannomas

Tercer ventriculostomía endoscópica en la hidrocefalia secundaria a schwannomas vestibulares

Ernesto Enrique Horta-Tamayo<sup>1,2\*</sup> <https://orcid.org/0000-0002-1292-1689>

Diana Rosa Ortega-Raez<sup>2</sup> <https://orcid.org/0000-0002-6992-3570>

Luis Cesar Acosta-González<sup>2</sup> <https://orcid.org/0000-0002-6463-4243>

Orestes López-Piloto<sup>3</sup> <https://orcid.org/0000-0002-1889-5223>

Lismary Martínez-Valdés<sup>3</sup> <https://orcid.org/0000-0003-1964-4327>

Martha Suárez-Cruz<sup>1</sup> <https://orcid.org/0000-0002-4608-4903>

<sup>1</sup>Universidad de Ciencias Médicas de Holguín. Facultad de Ciencias Médicas "Mariana Grajales Coello". Holguin, Cuba.

<sup>2</sup>Hospital Clínico Quirúrgico "Lucía Iñiguez Landín". Holguin, Cuba.

<sup>3</sup>Instituto de Neurología y Neurocirugía "José Rafael Estrada González". Havana, Cuba.

\*Author for correspondence. Email: [ernestoht@infomed.sld.cu](mailto:ernestoht@infomed.sld.cu)

### ABSTRACT

**Introduction:** Treatment options for hydrocephalus related to posterior fossa tumors have been extensively studied in the pediatric population, but the value of endoscopic third ventriculostomy in hydrocephalus secondary to vestibular schwannoma in adults, is controversial. A systematic search of the medical literature was carried out in Pubmed/Medline and SciELO for the identification and inclusion of articles, in addition to the preprint servers bioRxiv and medRxiv. The following descriptors were used: "hydrocephalus" and "vestibular schwannomas" or "acoustic neuromas" or "acoustic neurinomas" and

<http://scielo.sld.cu>

<http://www.revmedmilitar.sld.cu>



“endoscopic third ventriculostomy”. The initial search found 195 articles. After selection, 5 articles were chosen for the study.

**Objective:** To specify the role of the endoscopic third ventriculostomy in hydrocephalus secondary to vestibular schwannomas.

**Development:** The articles included a total of 82 patients, in which an improvement of the symptoms was achieved in 86.6% of the cases. The decrease in ventricular diameter was reported in 82.9% of the cases and was only found explicit in 3 articles. Although the failure criteria used were varied, 2 of them predominated: the persistence of progressive symptomatic hydrocephalus and/or the need for shunt placement. Endoscopic third ventriculostomy failure only represented 14.6%.

**Conclusions:** Third ventriculostomy is an acceptable technique with relative success for the treatment of symptomatic obstructive hydrocephalus secondary to vestibular schwannomas.

**Keywords:** endoscopic third ventriculostomy; hydrocephalus; vestibular schwannoma.

## RESUMEN

**Introducción:** Las opciones de tratamiento para la hidrocefalia relacionada con tumores de fosa posterior han sido ampliamente estudiadas en la población pediátrica, pero es controvertido el valor de la tercer ventriculostomía endoscópica, en la hidrocefalia secundaria a schwannoma vestibular en adultos, previo a la resección del tumor. Se realizó una búsqueda sistemática de la literatura médica en Pubmed/Medline y SciElo para la identificación e inclusión de artículos, además de los servidores de preprint bioRxiv y medRxiv. Se utilizaron los siguientes descriptores: “*hydrocephalus*” y “*vestibular schwannomas*” o “*acoustic neuromas*” o “*acoustic neurinomas*” y “*endoscopic third ventriculostomy*”. La búsqueda inicial encontró 195 artículos. Después de la selección, se eligieron 5 artículos para el estudio.

**Objetivo:** Especificar el papel de la tercer ventriculostomía endoscópica en la hidrocefalia secundaria a schwannomas vestibulares.

**Desarrollo:** Los artículos incluyeron un total de 82 pacientes, en los que se logró una mejoría de los síntomas en el 86,6 % de los casos. La disminución del diámetro ventricular se reportó en el 82,9 % de los casos y solo se encontró explícita en 3 artículos. Aunque los criterios de fracaso utilizados fueron variados, predominaron dos de ellos: la persistencia de hidrocefalia sintomática progresiva o la necesidad



de colocación de derivación. La falla de la tercer ventriculostomía endoscópica solo representó el 14,6 %.

**Conclusiones:** La tercer ventriculostomía endoscópica es una técnica aceptable y con relativo éxito para el tratamiento de la hidrocefalia obstructiva sintomática secundaria a schwannomas vestibulares.

**Palabras clave:** tercer ventriculostomía endoscópica; hidrocefalia; schwannoma vestibular.

Recibido: 22/03/2023

Aprobado: 23/08/2023

## INTRODUCTION

The frequency and treatment options for hydrocephalus related to posterior fossa tumors have been extensively studied in the pediatric population, but the value of endoscopic third ventriculostomy in hydrocephalus secondary to vestibular schwannoma in adults, is controversial.<sup>(1,2,3)</sup> On the other hand, certain results show a decrease in the incidence of perioperative complications, including persistent post-surgical hydrocephalus.<sup>(4,5,6,7,8)</sup>

On this topic, some authors suggest the “unnecessary” nature of this procedure, taking into account that persistent hydrocephalus after tumor excision is only 10-30%, so endoscopic third ventriculostomy (ETV) would only be useful in these cases.<sup>(9)</sup> However, the literature regarding posterior fossa tumors in adults is scarce. Some studies report that the success rates of ETV for obstructive hydrocephalus in this group range between 70 and 90%.<sup>(10,11,12)</sup>

However, these studies do not present a detailed analysis of the intervened tumors and they are not consecutive series, which limits their interpretation. In others, they focus on the placement of external ventricular drains or shunt systems, and do not consider ETV as an option.<sup>(13)</sup>

In particular, studies on the management of hydrocephalus due to vestibular schwannomas are very few, and only report the frequency of hydrocephalus, but do not offer information on its treatment. Sometimes, some authors exclude those cases with preoperative hydrocephalus or include patients with tumors that did not subsequently receive surgery for tumor resection.<sup>(14,15)</sup>

<http://scielo.sld.cu>

<http://www.revmedmilitar.sld.cu>



In recent years, there has been no consensus on the optimal surgical technique for hydrocephalus secondary to vestibular schwannoma, especially the performance of ETV, which is why there is an urgent need to specify the indications for this surgical technique.

A systematic search of the English/Spanish medical literature was carried out in Pubmed/Medline and SciELO, for the identification and inclusion of articles, in addition to the preprint servers bioRxiv and medRxiv (last updated on October 5, 2022), under the Preferred Reporting Items for Systematic Reviews and Meta-Analysis (PRISMA) Statement Guidelines.<sup>(16)</sup> (Fig. 1). The references of the selected articles were also reviewed.

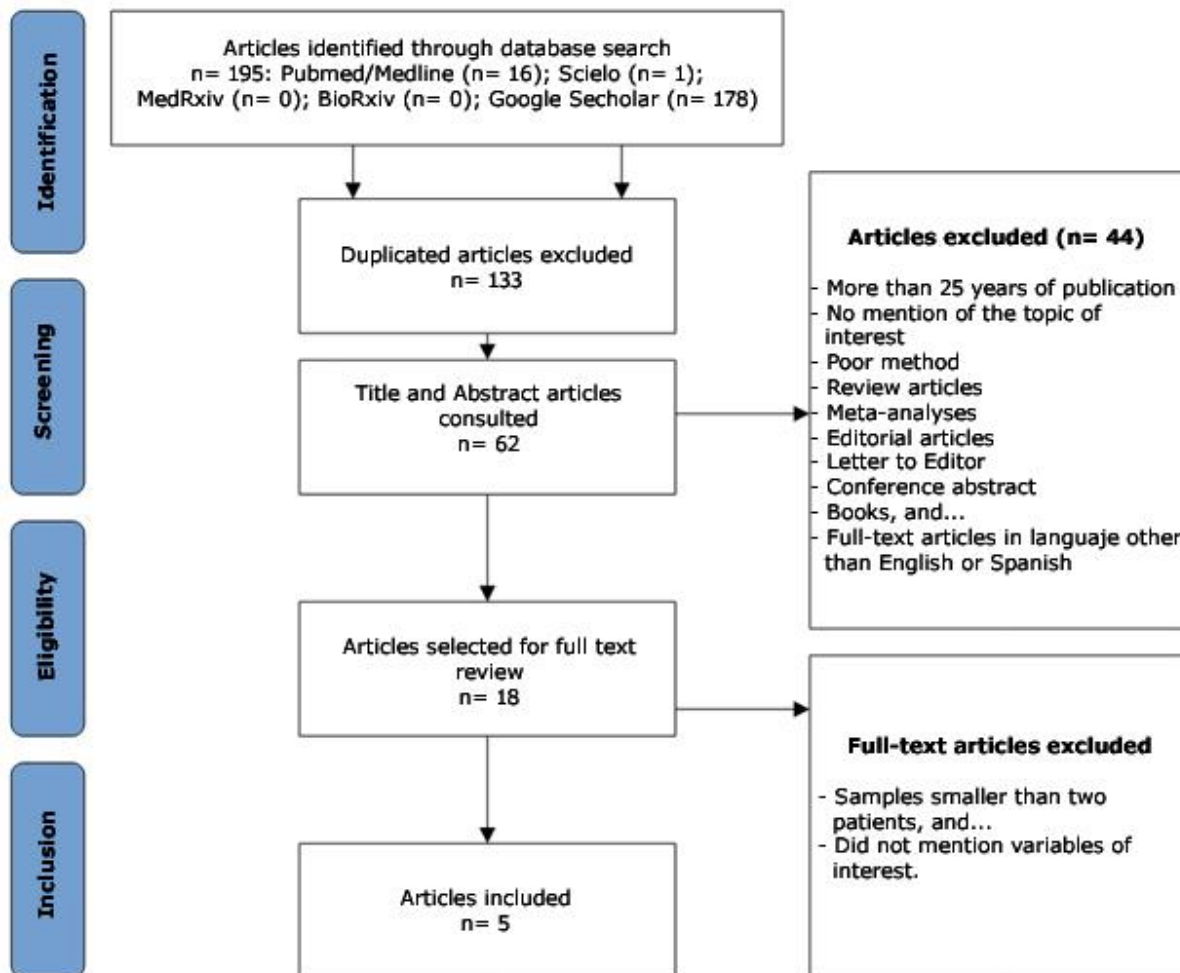


Fig. 1 - PRISMA diagram.



The following descriptors were used: “hydrocephalus” and “vestibular schwannomas” or “acoustic neuromas” or “acoustic neurinomas” and “endoscopic third ventriculostomy”.

Two investigators independently reviewed the titles and abstracts identifying relevant articles. Editorial articles, letters to the editor, books, reviews, meta-analyses, and case reports were excluded.

After identifying the studies that met the inclusion criteria, 2 authors reviewed the selected articles in full text. A third author resolved points of disagreement, both in selection and data extraction.

The following information was collected from each article: authors and year of publication, sample number, percentage of patients with improvement after ETV, those who presented decreased ventricular diameter later EVT, and those who presented failure of ETV. In addition, the follow-up period of the cases was collected, as well as the criteria used to define ETV failure.

If the email address of the contact author was available in the article text, messages were sent to request non-explicit information. If no response was received, a second and final message was sent 21 days later.

Overall, the quality of the studies was assessed, using The Grades of Recommendations, Assessment, Development and Evaluation (GRADE) to carry out the certification of the evidence.<sup>(17)</sup>

After excluding articles that did not mention variables of interest and those with a sample of less than 2 patients, a total of 5 articles were included.

The search results are displayed in the PRISMA diagram (Fig. 1). The initial search found 195 articles, removal of duplicates excluded 133 articles, and the remaining 62 were reviewed. Those articles that did not meet the selection criteria according to the explicit information in the title or abstract were excluded, reviewing a total of 18 full-text articles. After full-text review, 5 articles were chosen for the study. Regarding non-explicit data, only 1 author responded, but was unable to provide new information.

The aim of the review is to specify the role of the endoscopic third ventriculostomy in hydrocephalus secondary to vestibular schwannomas.



## DEVELOPMENT

The articles included a total of 82 patients, where an improvement of the symptoms was achieved in 86.6% of the cases (table 1). The decrease in ventricular diameter was reported in 82.9% of the cases and was only found explicit in 3 articles. Although the failure criteria used were varied (table 2), two of them predominated: the persistence of progressive symptomatic hydrocephalus and/or the need for shunt placement. EVT failure only represented 14.6% (12 patients). *Shin et al.*<sup>(18)</sup> did not state the follow-up period, but in the remaining studies it averaged 59.8 months.

**Table 1** - Characteristics of the studies with ETV performed in hydrocephalus secondary to vestibular schwannoma (VS)

Authors/year	Sample (n)	Symptom improvement after ETV (%)	Decrease in ventricular diameter later ETV (%)	ETV failure (%)	Average follow-up period (months)
Hayhurst et al. <sup>(19)</sup> /2006	8	100	-	37.5	34
Ardakani et al. <sup>(20)</sup> /2014	8	-	62.5	25	6
Marx et al. <sup>(21)</sup> /2017	6	50	33.3	0	132
Marx et al. <sup>(22)</sup> /2018	3	100	-	0	67.2
Shint et al. <sup>(18)</sup> /2021	57	100	100	12	-

**Table 2** - Criteria used to define ETV failure in the studies

Authors/year	Criteria used to define ETV failure
<i>Hayhurst et al.</i> <sup>(13)</sup> 2006	Progressive symptoms of hydrocephalus Cerebrospinal fluid (CSF) fistula that requires placement of a shunt for control
<i>Ardakani et al.</i> <sup>(14)</sup> 2014	Death related to ETV Need to install derivative systems
<i>Marx et al.</i> <sup>(15)</sup> /2017	Progressive symptoms of hydrocephalus that require placement of a shunt
<i>Marx et al.</i> <sup>(16)</sup> /2018	Persistent hydrocephalus
<i>Shint et al.</i> <sup>(12)</sup> /2021	Symptomatic or imaging hydrocephalus secondary to tumor resection surgery, despite the application of a derivative procedure prior to it

The frequency of hydrocephalus secondary to posterior fossa tumors in pediatric patients is 70-90%, but data in the adult population are lacking.<sup>(5,14,23)</sup>



The rate of hydrocephalus in vestibular schwannomas ranges from 3.7-42 %, but at present, with the accessibility to diagnostic means, an incidence of 2.5% has been reported.<sup>(15)</sup>

In societies with easy access to health services, the symptomatic periods before diagnosis are shortened, resulting in lesions with small diameters in the initial studies and, therefore, less incidence of hydrocephalus.<sup>(24,25)</sup> However, in a series of 77 patients with vestibular schwannomas with diameters less than 3 cm, 9 cases showed communicating hydrocephalus.<sup>(26)</sup>

The cause of this non-obstructive (communicating) hydrocephalus could be the increase in protein levels of the cerebrospinal fluid,<sup>(15,26)</sup> especially in small tumors.<sup>(15)</sup> Other theories include alterations in the flow of cerebrospinal fluid (CSF) in the basal cisterns, associated with the tumor, or increases in fibrinogen levels, meningeal adhesions caused by recurrent tumor bleeding and protein-induced arachnoiditis.<sup>(14)</sup>

However, in a study published in 2018 by *Marx et al.*<sup>(22)</sup> which included 243 adult patients, 52 had hydrocephalus, this being obstructive in all cases. Since the pioneering article by *Sainte-Rose et al.*<sup>(27)</sup> who showed that ETV before resective surgery of posterior fossa tumors in pediatric patients decreased the risks of perioperative complications and persistent hydrocephalus, an intense debate about its use in such circumstances can be found in literature. The point of greatest controversy is whether or not ETV is justified prior to tumor resection surgery, taking into account that only 20-30% of patients suffer from persistent hydrocephalus.<sup>(14)</sup>

This issue has not yet been resolved in adult patients. However, in previous works, the authors have shown that ETV in cases with posterior fossa tumors is a viable option, although these are only initial results.<sup>(11)</sup>

*Norren et al.*<sup>(28)</sup> reported that in most patients it is the tumor that produces hydrocephalus, and not its treatment. For this reason, in their series they only inserted a shunt in 9.2% of the cases that received radiosurgery for Gamma Knife, and in 5.5% before receiving it. The peritumoral reaction due to radiotherapy required a shunt in only 1.4% of cases.

*Pirouzmand et al.*<sup>(29)</sup> evaluated the contribution of radiosurgery in the development of hydrocephalus, but did not find significance ( $p= 0.1$ ), with only 6.5% of the cases that received radiosurgery, those that presented hydrocephalus, lower than those that received only radiosurgery, observation (10.7%) and



microsurgery (13.8%).

Although several authors suggest that this symptomatic hydrocephalus could be explained by the hypothesis of the release of proteins and cellular debris as a result of radiation-induced necrosis, such a mechanism has not been proven. It is also proposed that such a mechanism is not exclusive to the effect of radiotherapy, and that these substances can also be released by the tumor itself in cases treated conservatively or by the lesion in cases undergoing surgery.<sup>(30,31,32,33)</sup>

All types of hydrocephalus can be treated by placing a shunt, but the failure of this system is practically inevitable during the patient's life. On the other hand, advances in neuroendoscopy have made it possible to manage hydrocephalus without the need to implant permanent shunt systems. A few years ago, ETV was established as the ideal form of treatment for obstructive hydrocephalus, but recent publications have shown its use to treat communicating forms in selected patients.<sup>(11,34)</sup>

Treatment options in hydrocephalus secondary to vestibular schwannoma (VS) vary from placement of an external ventricular drain to ventriculoperitoneal shunt (VPS) prior to surgery or radiosurgery, or primary tumor resection, with subsequent treatment of hydrocephalus in persistent cases. As hydrocephalus associated with ventricular schwannomas is theoretically reversible, the latter option seems reasonable, with the added benefits of preventing potential complications associated with more invasive procedures or eventual dependence on the shunt.<sup>(15)</sup>

In recent years, ETV has gained interest in this regard, but if the experience of performing neuroendoscopic procedures is low, the recommendation is to use external ventricular drainage.<sup>(14)</sup>

Not all patients require placement of a shunt system despite ventriculomegaly, being asymptomatic, but those with acute hydrocephalus or papilledema will require intervention. Some authors debate the algorithm used for this type of hydrocephalus, when a microsurgical excision has been planned, including the placement of the shunt before surgery, tumor resection before or after the bypass, or VPS only for those cases with progressive post-surgical hydrocephalus.<sup>(14,15)</sup>

Hayhurst et al.,<sup>(19)</sup> in 2006, published a retrospective study of 11 patients with hydrocephalus secondary to cerebellopontine angle tumors, where 8 had a vestibular schwannoma, and this subgroup showed a success rate of 62.5%. The remaining 3 patients did not show a cerebrospinal fluid leak or pseudomeningocele after resection, so ETV could avoid the need for perioperative external ventricular drainage.





In contrast to these results, other authors have reported pseudo-meningocele and cerebrospinal fluid leak rates of 17% and 21%, respectively, despite external ventricular drainage (EVD) placement.<sup>(29)</sup>

If the patient is not a candidate for tumor resection, due to advanced age or high co-morbidities, ETV can be a safe alternative to shunt. *Hayhurst et al.*<sup>(19)</sup> found no significant differences between primary ETV and those performed for hydrocephalus after radiotherapy, despite the fact that the number of patients is low.

*Ardakani et al.*<sup>(20)</sup> published a series of 8 cases, where they obtained the same success rate as *Hayhurst et al.*<sup>(19)</sup> but all the failed cases (3 patients) were related to meningitis. One of them died, and the other 2 required the placement of a shunt, which does not correspond to the main cause related to ETV failure: stoma closure due to gliosis or adhesions.<sup>(35,36)</sup>

In 2021, *Shin et al.*<sup>(18)</sup> published the largest institutional study on the treatment of hydrocephalus secondary to vestibular schwannomas, including 57 patients who received ETV, where 34 showed a communicating pattern and 23 obstructive. All cases were symptomatic. These authors report a failure rate of only 12% (7 patients). The analysis of the predictive factors showed that regardless of the technique used, an Evans index greater than or equal to 0.4, the cystic appearance of the tumor and a subtotal resection, may be related to the appearance of persistent hydrocephalus. A great limitation of this study is the non-declaration of the follow-up time of the cases.

*Marx et al.*<sup>(21)</sup> in 2017, published a series of 40 cases of ETV in patients with hydrocephalus secondary to posterior fossa tumors, where 6 presented hydrocephalus or ventricular dilatation due to a vestibular schwannoma, but only 3 showed symptoms. No patient received a bypass system in the postoperative period, which averaged 132 months. These authors do not recommend the use of prophylactic ETV in asymptomatic patients, reserving elective surgery in these cases. The following year they presented a retrospective study of 52 patients with hydrocephalus diagnosed before or after excision surgery for posterior fossa tumors, who received various forms of treatment. Only 8,6% of the cases in the series (3 patients) had a diagnosis of vestibular schwannoma and the technique used was ETV. Two of them were symptomatic before tumor resection, performed primarily, and in the remaining one, hydrocephalus presented 17 days after tumor resection. These researchers demonstrated in their series that despite an incidence of hydrocephalus of 21.4%, its persistent nature after tumor resection was very low (5.7%),



which makes the use of ETV questionable. But they also observed a low incidence of surgical complications, especially cerebrospinal fluid leaks. However, it is difficult to compare the results, due to the wide heterogeneity of histological diagnoses of the subjects included in the study, however, they recommend the use of ETV in emergent situations with decompensated obstructive hydrocephalus, to then perform tumor resection surgery in the following days.<sup>(22)</sup>

One of the great limitations of the two previous studies is that these patients were included in the pool of cases, not performing any subgroup analysis, which makes it difficult to draw conclusions.

Another topic under debate is the management of persistent hydrocephalus. Its appearance, after surgical exeresis, is very infrequent. It may be related to anatomical distortion of the fourth ventricle, ependymal adhesions in it, or contamination of the arachnoid space by blood and its degradation products. Sometimes, the normalization of ventricular size may require a long period of time due to the decrease in ventricular elasticity caused by the chronicity of hydrocephalus.<sup>(37)</sup>

In a series published by *Harati et al.*<sup>(38)</sup> in 2017 that included a total of 49 patients with large vestibular schwannomas, only 16 showed obstructive hydrocephalus and only 6 required VPS for persistent hydrocephalus.

A larger number of cases in prospective cohorts is needed to issue clear recommendations.

In the authors' view, based on the studies presented, ETV prior to surgery for large ventricular schwannomas may be warranted in selected patients with symptomatic obstructive hydrocephalus. However, ETV does not eliminate the risk of persistent hydrocephalus after tumor resection, which is relatively low. In a context with limited resources, where it is difficult to plan excision surgery within 72 hours of diagnosis and the high cost of referral systems, ETV acquires an added value. Based on this review, a possible algorithm in these cases is shown in figure 2.

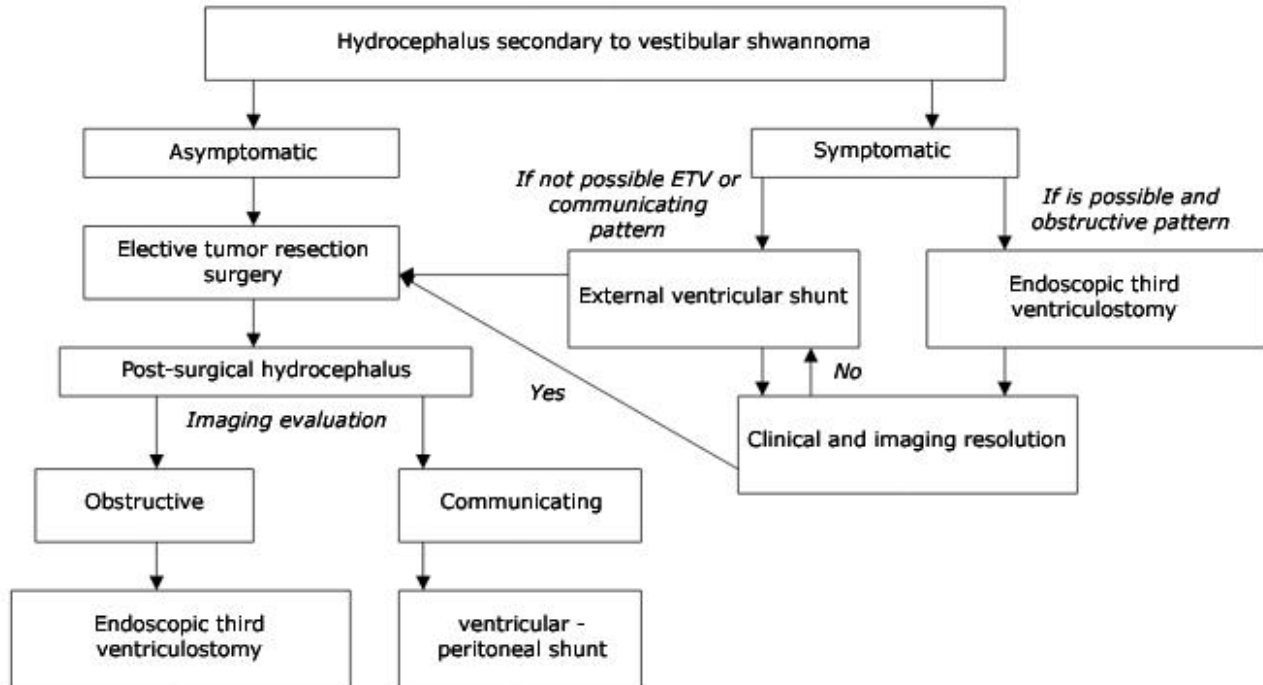


Fig. 2 - Possible algorithm in hydrocephalus secondary to vestibular schwannomas.

In conclusions, ETV is an acceptable technique for the treatment of symptomatic obstructive hydrocephalus secondary to ventricular schwannomas. Studies in this regard reveal relative success.

## BIBLIOGRAPHIC REFERENCES

1. Rennert RC, Brandel MG, Srinivas S, Prajapati D, Jammal OMA, Brown NJ, et al. Palliative endoscopic third ventriculostomy for pediatric primary brain tumors: a single-institution case series. *J Neurosurg Pediatr.* 2021 [access: 02/02/2023];28(4):387-94. Available at: <https://thejns.org/pediatrics/view/journals/j-neurosurg-pediatr/28/4/article-p387.xml>
2. Taguchi A, Kinoshita Y, Amatya VJ, Takayasu T, Takano M, Yonezawa U, et al. Intratumoral Hemorrhage After Endoscopic Third Ventriculostomy for Obstructive Hydrocephalus Caused by Brain Tumors. *World Neurosurg.* 2022 [access: 02/02/2023]; 158:e256-64. Available at: <https://www.sciencedirect.com/science/article/pii/S1878875021016739>



3. Tabakow P, Weiser A, Burzynska M, Blauciak P. Endoscopic third ventriculostomy before surgery of third ventricle and posterior fossa tumours decreases the risk of secondary hydrocephalus and early postoperative complications. *Neurosurg Rev.* 2022; 45(1):771-81. DOI: 10.1007/s10143-021-01570-w
4. Sherrod BA, Iyer RR, Kestle JRW. Endoscopic third ventriculostomy for pediatric tumor-associated hydrocephalus. *Neurosurg Focus.* 2020 [access: 02/02/2023]; 48(1):E5. Available at: <https://thejns.org/focus/view/journals/neurosurg-focus/48/1/article-pE5.xml>
5. Srinivasan HL, Foster MT, Baarsen K van, Hennigan D, Pettorini B, Mallucci C. Does pre-resection endoscopic third ventriculostomy prevent the need for post-resection CSF diversion after pediatric posterior fossa tumor excision? A historical cohort study and review of the literature. *J Neurosurg Pediatr.* 2020 [access: 02/02/2023]; 25(6):615-24. Available at: <https://thejns.org/pediatrics/view/journals/j-neurosurg-pediatr/25/6/article-p615.xml>
6. Frisoli F, Kakareka M, Cole KA, Waanders AJ, Storm PB, Lang SS. Endoscopic third ventriculostomy prior to resection of posterior fossa tumors in children. *Childs Nerv Syst.* 2019; 35(5):789-94. DOI: 10.1007/s00381-019-04125-z
7. Guida L, Roux FE, Massimino M, Marras CE, Sganzerla E, Giussani C. Safety and Efficacy of Endoscopic Third Ventriculostomy in Diffuse Intrinsic Pontine Glioma Related Hydrocephalus: A Systematic Review. *World Neurosurg.* 2019 [access: 02/02/2023]; 124:29-35. Available at: <https://www.sciencedirect.com/science/article/pii/S187887501832919X>
8. Dhandapani M, Yagnick NS, Mohanty M, Ahuja CK, Dhandapani S. Clinical Outcome, Cognitive Function, and Quality of Life after Endoscopic Third Ventriculostomy versus Ventriculo-Peritoneal Shunt in Non-Tumor Hydrocephalus. *Neurol India.* 2021; 69(Supplement):S556-60. DOI: 10.4103/0028-3886.332271
9. Won SY, Dubinski D, Behmanesh B, Bernstock JD, Seifert V, Konczalla J, et al. Management of hydrocephalus after resection of posterior fossa lesions in pediatric and adult patients—predictors for development of hydrocephalus. *Neurosurg Rev.* 2020; 43(4):1143-50. DOI: 10.1007/s10143-019-01139-8
10. Grand W, Leonardo J, Chamczuk AJ, Korus AJ. Endoscopic Third Ventriculostomy in 250 Adults With Hydrocephalus: Patient Selection, Outcomes, and Complications. *Neurosurgery.* 2016; 78(1):109-



19. DOI: 10.1227/NEU.0000000000000994

11. Tamayo EEH, Gonzalez LCA, Raez DRO, Rodríguez-Santillán LB. Tercer ventriculostomía endoscópica en hidrocefalia secundaria a tumores de fosa posterior en adultos. *Rev Cienc Médicas Pinar Río*. 2021 [access: 02/02/2023]; 25(6):5273. Available at:

<http://www.revcompinar.sld.cu/index.php/publicaciones/article/view/5273>

12. Lu L, Chen H, Weng S, Xu Y. Endoscopic Third Ventriculostomy versus Ventriculoperitoneal Shunt in Patients with Obstructive Hydrocephalus: Meta-Analysis of Randomized Controlled Trials. *World Neurosurg*. 2019 [access: 02/02/2023]; 129:334-40. Available at:

<https://www.sciencedirect.com/science/article/pii/S187887501931263X>

13. Saad H, Bray DP, McMahon JT, Philbrick BD, Dawoud RA, Douglas JM, et al. Permanent Cerebrospinal Fluid Diversion in Adults With Posterior Fossa Tumors: Incidence and Predictors. *Neurosurgery*. 2021 [access: 02/02/2023]; 89(6):987. Available at:

[https://journals.lww.com/neurosurgery/Abstract/2021/12000/Permanent\\_Cerebrospinal\\_Fluid\\_Diversion\\_in\\_Adults.6.aspx](https://journals.lww.com/neurosurgery/Abstract/2021/12000/Permanent_Cerebrospinal_Fluid_Diversion_in_Adults.6.aspx)

14. Won SY, Dubinski D, Behmanesh B, Bernstock JD, Seifert V, Konczalla J, et al. Management of hydrocephalus after resection of posterior fossa lesions in pediatric and adult patients—predictors for development of hydrocephalus. *Neurosurg Rev*. 2020; 43(4):1143-50. DOI: 10.1007/s10143-019-01139-8

15. di Russo P, Fava A, Vandenbulcke A, Miyakoshi A, Kohno M, Evins AI, et al. Characteristics and management of hydrocephalus associated with vestibular schwannomas: a systematic review. *Neurosurg Rev*. 2021; 44(2):687-98. DOI: 10.1007/s10143-020-01287-2

16. Tetzlaff J, Page M, Moher D. The PRISMA 2020 statement: development of and key changes in an update guideline for reporting systematic reviews and meta-analyses. *Value Health*. 2020 [access: 02/02/2023]; 23:S312-3. Available at: [https://www.valueinhealthjournal.com/article/S1098-3015\(20\)31342-5/fulltext](https://www.valueinhealthjournal.com/article/S1098-3015(20)31342-5/fulltext)

17. Hilton Boon M, Thomson H, Shaw B, Akl EA, Lhachimi SK, López-Alcalde J, et al. Challenges in applying the GRADE approach in public health guidelines and systematic reviews: a concept article from the GRADE Public Health Group. *J Clin Epidemiol*. 2021 [access: 02/02/2023]; 135:42-53.

---

<http://scielo.sld.cu>

<http://www.revmedmilitar.sld.cu>



Available at: <https://www.sciencedirect.com/science/article/pii/S0895435621000032>

18. Shin DW, Song SW, Chong S, Kim YH, Cho YH, Hong SH, et al. Treatment Outcome of Hydrocephalus Associated with Vestibular Schwannoma. *J Clin Neurol Seoul Korea*. 2021 [access: 02/02/2023]; 17(3):455-62. Available at: <https://www.ncbi.nlm.nih.gov/pmc/articles/PMC8242310/>
19. Hayhurst C, Javadpour M, O'Brien DF, Mallucci CL. The role of endoscopic third ventriculostomy in the management of hydrocephalus associated with cerebellopontine angle tumours. *Acta Neurochir*. 2006; 148(11):1147-50. DOI: 10.1007/s00701-006-0886-2
20. Ardakani SK, Aoude A, Ghodsi SM, Abdollahzadeh S, Khoshnevisan A. Endoscopic Third Ventriculostomy in Patients With Vestibular Schwannoma and Hydrocephalus: A Clinical Trial. *Neurosurg Q*. 2014 [access: 02/02/2023]; 24(4):267-71. Available at: [https://journals.lww.com/neurosurgery-quarterly/Abstract/2014/11000/Endoscopic\\_Third\\_Ventriculostomy\\_in\\_Patients\\_With.10.aspx](https://journals.lww.com/neurosurgery-quarterly/Abstract/2014/11000/Endoscopic_Third_Ventriculostomy_in_Patients_With.10.aspx)
21. Marx S, Damaty AE, Manwaring J, Refaee EE, Fleck S, Fritsch M, et al. Endoscopic Third Ventriculostomy before Posterior Fossa Tumor Surgery in Adult Patients. *J Neurol Surg Part Cent Eur Neurosurg*. 2018 [access: 02/02/2023]; 79(2):123-9. Available at: <http://www.thieme-connect.de/DOI/DOI?10.1055/s-0037-1608786>
22. Marx S, Reinfelder M, Matthes M, Schroeder HWS, Baldauf J. Frequency and treatment of hydrocephalus prior to and after posterior fossa tumor surgery in adult patients. *Acta Neurochir*. 2018; 160(5):1063-71. DOI: 10.1007/s00701-018-3496-x
23. Anania P, Battaglini D, Balestrino A, D'Andrea A, Prior A, Ceraudo M, et al. The role of external ventricular drainage for the management of posterior cranial fossa tumours: a systematic review. *Neurosurg Rev*. 2021; 44(3):1243-53. DOI: 10.1007/s10143-020-01325-z
24. Nair P, Singh DK, Sahu RN, Kumar R, Behari S, Jaiswal AK, et al. Large vestibular schwannomas and hydrocephalus: Lessons learnt from a single centre experience. *Indian J Neurosurg*. 2014 [access: 02/02/2023]; 03(1):19-24. Available at: <http://www.thieme-connect.de/DOI/DOI?10.4103/2277-9167.131997>
25. Shin DW, Song SW, Chong S, Kim YH, Cho YH, Hong SH, et al. Treatment Outcome of Hydrocephalus Associated with Vestibular Schwannoma. *J Clin Neurol Seoul Korea*. 2021 [access:

<http://scielo.sld.cu>

<http://www.revmedmilitar.sld.cu>



02/02/2023]; 17(3):455-62. Available at: <https://www.ncbi.nlm.nih.gov/pmc/articles/PMC8242310/>

26. Taniguchi M, Nakai T, Kohta M, Kimura H, Kohmura E. Communicating Hydrocephalus Associated with Small- to Medium-Sized Vestibular Schwannomas: Clinical Significance of the Tumor Apparent Diffusion Coefficient Map. *World Neurosurg.* 2016; 94:261-7. DOI:

10.1016/j.wneu.2016.07.012

27. Sainte-Rose C, Cinalli G, Roux FE, Maixner R, Chumas PD, Mansour M, et al. Management of hydrocephalus in pediatric patients with posterior fossa tumors: the role of endoscopic third ventriculostomy. *J Neurosurg.* 2001; 95(5):791-7. DOI: 10.3171/jns.2001.95.5.0791

28. Yang HC, Wu CC, Lee CC, Huang HE, Lee WK, Chung WY, et al. Prediction of pseudoprogression and long-term outcome of vestibular schwannoma after Gamma Knife radiosurgery based on preradiosurgical MR radiomics. *Radiother Oncol.* 2021 [access: 02/02/2023]; 155:123-30.

Available at: <https://www.sciencedirect.com/science/article/pii/S0167814020308884>

29. Pirouzmand F, Tator CH, Rutka J. Management of hydrocephalus associated with vestibular schwannoma and other cerebellopontine angle tumors. *Neurosurgery.* 2001; 48(6):1253-1254. DOI: 10.1097/00006123-200106000-00010

30. Marshalik M, DiManna K, Wagner J. Hydrocephalus After Gamma Knife Radiosurgery for Vestibular Schwannoma: Favorable Outcomes After Shunt Placement. *Cureus.* 2022; 14(5):e25415. DOI: 10.7759/cureus.25415

31. Kim J, Woo B, Ji S, Hwang K, Kim YH, Han JH, et al. Communicating Hydrocephalus Following Treatment of Cerebellopontine Angle Tumors. *World Neurosurg.* 2022 [access: 02/02/2023]; 165:e505-11. Available at: <https://www.sciencedirect.com/science/article/pii/S1878875022008737>

32. Shimizu Y, Miyamori T, Yamano J. Hydrocephalus after Gamma Knife Radiosurgery for Schwannoma. *Asian J Neurosurg.* 2019 [access: 02/02/2023]; 14(2):487-90. Available at: <https://www.ncbi.nlm.nih.gov/pmc/articles/PMC6516019/>

33. De Sanctis P, Green S, Germano I. Communicating hydrocephalus after radiosurgery for vestibular schwannomas: does technique matter? A systematic review and meta-analysis. *J Neurooncol.* 2019; 145(2):365-73. DOI: 10.1007/s11060-019-03305-w

34. Horta-Tamayo EE, Acosta-González LC, Sarmiento-Leyva F, Ortega-Raez DR, Leyva-Mérida A,



Marrero-Ramayo A. Tercer ventriculostomía endoscópica en la hidrocefalia de presión normal idiopática. Rev Arch Méd Camagüey. 2022 [access: 02/02/2023]; 26:e8666. Available at:

<http://revistaamc.sld.cu/index.php/amc/article/view/8666>

35. Rahman MM, Khan SIMKN, Khan RA, Islam R, Sarker MH. Endoscopic third ventriculostomy in children: problems and surgical outcome: analysis of 34 cases. Chin Neurosurg J. 2021; 7(1):3. DOI: 10.1186/s41016-020-00228-8

36. Salah M, Elhuseny AY, Youssef EM. Endoscopic third ventriculostomy for the management of hydrocephalus secondary to posterior fossa tumors: A retrospective study. Surg Neurol Int. 2022 [access: 02/02/2023]; 13:65. Available at: <https://www.ncbi.nlm.nih.gov/pmc/articles/PMC8888306/>

37. Fukuda M, Oishi M, Kawaguchi T, Watanabe M, Takao T, Tanaka R, et al. Etiopathological factors related to hydrocephalus associated with vestibular schwannoma. Neurosurgery. 2007; 61(6):1186-92. DOI: 10.1227/01.neu.0000306096.61012.22

38. Harati A, Scheufler KM, Schultheiss R, Tonkal A, Harati K, Oni P, et al. Clinical features, microsurgical treatment, and outcome of vestibular schwannoma with brainstem compression. Surg Neurol Int. 2017 [access: 02/02/2023]; 8:45. Available at:

<https://www.ncbi.nlm.nih.gov/pmc/articles/PMC5402336/>

### Conflict of interests

Authors declare that does not exist an interest conflict. The authors received no funding for the development of this review.