

## **Infective endocarditis in native mitral valve by *Hafnia alvei***

### **Endocarditis infecciosa en válvula nativa mitral por *Hafnia alvei***

**Teresa Suárez Díaz,<sup>I</sup> Junior Vega Jiménez,<sup>I</sup> Rodolfo Vega Candelario,<sup>II</sup> Yanet Acosta Piedra<sup>I</sup>**

<sup>I</sup> Hospital Militar "Dr. Mario Muñoz Monroy". Matanzas, Cuba.

<sup>II</sup> Hospital General Docente "Capitán Roberto Rodríguez Fernández". Morón, Ciego de Ávila, Cuba.

---

#### **ABSTRACT**

We report the case of a 40-year-old male patient with no prior personal pathological history, who had a prolonged febrile syndrome without being associated with other important clinical features. He was diagnosed with subacute bacterial endocarditis in the native mitral valve by an atypical pathogen: *Hafnia Alvei*. After an exhaustive review of the bibliography of the last 20 years corresponding to the Cuban medical journals, we conclude that we are facing the first clinical case of this type published in Cuba.

**Keywords:** *Hafnia alvei*; infective endocarditis.

---

#### **RESUMEN**

Se presenta el caso clínico de un paciente masculino de 40 años de edad, sin antecedentes patológicos personales, portador de un síndrome febril prolongado sin asociarse a otros elementos clínicos de importancia. Se le diagnosticó una endocarditis bacteriana subaguda en válvula mitral nativa por un germen patógeno atípico: *Hafnia alvei*. Tras realizar una exhaustiva revisión de la bibliografía de los

últimos 20 años correspondiente a las revistas médicas cubanas, se concluye que estamos frente al primer caso clínico de este tipo publicado en Cuba.

**Palabras clave:** *Hafnia alvei*; endocarditis infecciosa.

---

## INTRODUCTION

*Hafnia alvei* (*H. alvei*) is a Gram-negative bacillus, aerobic facultative, mobile due to perimeter flagella, not sporulated. Only species of the genus *Hafnia*, from the family *Enterobacteriaceae*, having previously received other names such as *Paracolon aerogenoides* and *Enterobacter hafnia*, until the development of molecular biology techniques, which determined its definition as a new genus. Its name comes from the Latin "*alveus*" that means hive.<sup>1,2</sup>

In the pathogenesis of *H. alvei* the lipopolysaccharide (LPS) corresponding to the antigen O is involved. According to the structure of the LPS of *H. alvei*, it has been divided into 39 O-serotypes 2. One faculty that contributes to the pathogenesis is the uptake of iron by siderophores.<sup>1</sup>

It identifies itself by detecting its own characteristics, including: negative oxidase, nitrate reductase and lysine decarboxylase, ornithine positive, fermenting several sugars including maltose, D-xylose, trehalose, D-mannitol, L-arabinose, L-Rhamnose, being unable to ferment lactose, raffinose, D-sorbitol, inositol and adonitol.<sup>1</sup>

Although it has been known to exist since 1954, it has only been recognized as a pathogen since 1991, especially in the form of acute gastroenteritis.<sup>3,4</sup> It is a microorganism colonizing the gastrointestinal tract and human oropharyngeal, where it is isolated frequently, although for years it has been considered a germ of low pathogenicity.<sup>2,4</sup> *H. alvei* has been found in different ecological niches, at the environmental level: water, soil and food. It is also part of the normal microbiota of mammals, birds, reptiles and fish. In humans it has been identified as an enteric species.<sup>1,5</sup>

It has been isolated from organic cultures (pharynx, bronchus, blood, urine and feces), producing infections in the vast majority of cases, in patients with chronic underlying diseases, immunosuppressed, pediatric and in relation to hospital stays and use of broad spectrum antibiotic therapy.<sup>1,6</sup>

Infective endocarditis is a microbial infection of the endocardium, in most cases of bacterial origin.<sup>7</sup> The clinical features of fever, changing murmur, splenomegaly, signs of peripheral embolization and multiple positive blood cultures are currently a rarity. In fact, it is estimated that physicians who strictly submit to these criteria did not suspect infectious endocarditis in up to 90 % of cases.<sup>8</sup> *Enterobacteriaceae* are not the most frequent causative germs of this disease.<sup>7,9</sup>

---

The following paper reports a case report of subacute infective endocarditis in a native mitral valve by *Hafnia alvei*.

## CLINICAL CASE

Reason for consultation: "fever". Patient of 40 years old, with white skin color, with no previous personal pathological history and agricultural worker, who started for 17 days with a fever of up to 40 degrees Celsius associated with an acute pharyngotonsillitis diagnosed in his health area, for which he was given treatment with crystalline penicillin (1 million IU) 1 bulb (im) intramuscular (im) every 6 hours for 48 hours and procaine penicillin (1 million IU) 1 bb im every 12 hours to complete 10 days.

Despite the indicated therapeutics, the subject remained febrile during and after treatment. The fever appeared at any time of day, intensifying in the evening, giving way with difficulty against oral antipyretics. This situation was accompanied by pulsatile frontal headache that disappeared when the fever subsided, as well as asthenia and anorexia. For these reasons he went to emergency of the *Hospital Militar "Dr. Mario Muñoz Monroy"* where was decided to admit him for better health care and treatment.

Physical examination: Normal.

Additional tests:

Hemoglobin: 14.1 grams per Liter.  
Leukogram with differential: global:  $10.6 \times 10^9$ .  
Polymorphonuclear cells: 0.59 % Lymphocytes: 0.33 % Eosinophils: 0.08 %  
Global sedimentation rate: 8 mm per hour.  
Absolute eosinophil count: 1.15  
Cholesterol: 4.86 mmol/L  
Triglycerides: 2.40 mmol/L  
Pyruvate glutamic transaminase: 23 IU  
Glutamic oxalacetic transaminase: 19 IU  
Gamma glutamyl transpeptidase (GGT): 12 IU  
Blood glucose: 4.15 mmol/L  
Initial creatinine: 101 micromol/L  
Uric acid: 454 mmol/L  
Urea: 5.10 mmol/L  
Total Protein: 81.8 g/L  
Albumin: 46 g/L  
LDH: 354  
Alkaline phosphatase: 90  
HIV: non-reactive  
VDRL: non-reactive  
Brucella test: negative  
Surface antigen (HBV): negative  
Antibody C (HCV): negative  
Serum blood culture: 3 positive *Hafnia alvei*.  
Sensitive to aminoglycosides, ciprofloxacin, meropenem, sulfaprim, ampicillin,

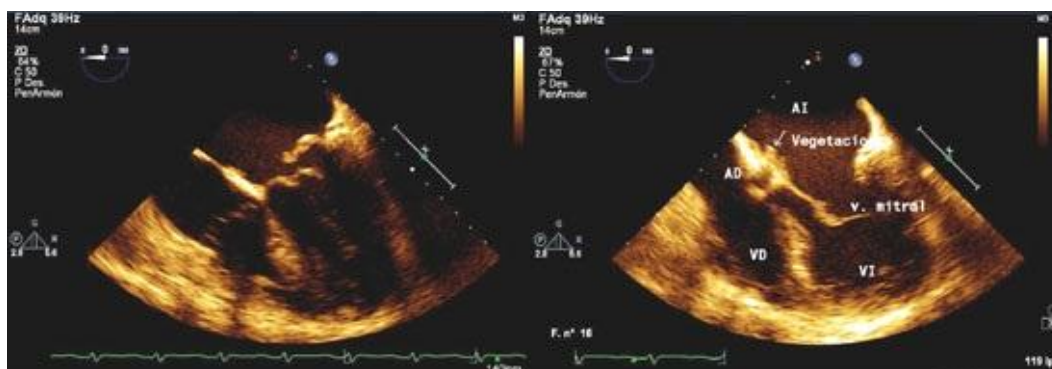
ceftriaxone, ceftazidime, cefazolin, vancomycin.

Resistant: do not report resistance (according to the discs used).

Chest X-rays postero-anterior view standing (remote from Telecardiogram): no alterations.

Abdominal ultrasound: shows no alterations in the abdominal organs.

Trans-esophageal echocardiogram: Images suggestive of vegetation on the posterior mitral valve with mild mitral regurgitation. (Performed at the *Instituto de Cardiología y Cirugía Cardiovascular* of Havana) ([Fig.](#)).



**Fig.** Image on the left shows that there is no image suggestive of right heart endocarditis (right ventricle, right atrium or tricuspid). Right image shows increased echogenicity; Greater than 2 mm in diameter; In mitral valve (on the auricular face of its posterior leaflet) highly suggestive of infective endocarditis.

Based on the above elements, a subacute bacterial endocarditis in the native mitral valve by *Hafnia alvei* was diagnosed. It was decided to start treatment with claforan (1 gram) 2 intravenous bb (ev) every 6 hours and Gentamycin (80 milligrams) 1 vial ev every 8 hours, based on the result of the antibiogram.

During treatment with claforan the patient presented an adverse reaction to this drug characterized by a reddish erythema in the facial region with the appearance of "butterfly wings" accompanied by pruritus. The case was discussed in conjunction with Internal Medicine and Cardiology services, reaching the consensus of starting treatment with vancomycin (500 mg) vv centrally for 4 weeks and maintaining gentamicin.

The clinical course was satisfactory. The evolutionary transthoracic echocardiogram reported: Anterior endocarditis on the mitral valve (posterior valve), a small image of high density persists corresponding with aseptic vegetation, and no mitral valvular incompetence.

He is discharged with follow-up by outpatient consultation by Internal Medicine service and annual evolution echocardiogram. During three years of evolution he has not presented medical complications.

## COMMENTS

The authors of the present paper consider of interest, due to its rarity, to communicate a case of subacute infective endocarditis in native valve, produced by *Hafnia alvei* in a non-immunocompromised individual. After an exhaustive review of the bibliography of the last 20 years corresponding to the Cuban medical journals published in the *Biblioteca Virtual de Salud* (Virtual Health Library) of Cuba<sup>10</sup> no similar case was reported, therefore the first clinical case of this type published in Cuba is presented.

The patient, according to the interview affirmed to be in continuous contact with animals (cattle) as agricultural worker, although it did not raise the existence of disease in its animals. It is possible that initial acute pharyngotonsillitis, repeated contact with animals, feces and frequent exposure to soil may have favored the development of infection.

After 4 weeks of treatment with third generation cephalosporins (initially), gentamicin and vancomycin, responded satisfactorily.

The *Duke* criteria are based mainly on the appropriate application of blood cultures and echocardiographic data.<sup>7,9,11</sup> The patient presented two major criteria and one minor (prolonged febrile syndrome), which is sufficient for the diagnosis of infective endocarditis. The follow up echocardiogram, once the treatment was concluded, showed no alterations.

The reported case does not meet the classic triad of fever, anemia and recent or changing murmur of infective endocarditis; in addition the causal germ is really very atypical.

Infections with this germ are very rare in clinical practice.<sup>12</sup> Occasionally they produce infections in humans.<sup>3</sup> In the cases described on medical literature the isolation of *H. alvei* is associated with polymicrobial flora, and it is difficult to establish its implication as a causal agent.<sup>6</sup>

This emerging microorganism can occasionally cause bacteremia, and it is very rare to isolate it from clinical samples, most of which is of unknown origin.<sup>5</sup>

This agent behaves as a rare opportunistic pathogen, which can cause nosocomial infections, including gastroenteritis, bacteremia, pneumonia, meningitis, wound infection, endophthalmitis and gluteal abscess.<sup>1</sup>

Nosocomial infections may be favored by invasive procedures such as bladder catheterization, mechanical ventilation, and vascular catheters, generally associated with prior antimicrobial therapy.<sup>5</sup> It has been described primarily in people with cancer, surgery, trauma, acute or chronic lung disease, cirrhosis, Hepatitis, meningitis, urinary infections and primary and secondary peritonitis.<sup>1,13</sup>

*Page*<sup>14</sup> reports a case of endocarditis produced by *Hafnia alvei* on a different mitral prosthetic valve but dislike the case in question, which is present in a native mitral valve and without demonstrated immunosuppression or comorbidity.

*Redondo*<sup>2</sup> shows a case of early nosocomial pneumonia in a post-surgical elderly man, as well as two cases of nosocomial pneumonia and respiratory super-infection in subjects with underlying chronic respiratory disease.<sup>6</sup> *Hidalgo*<sup>15</sup> presents a patient with bilateral pulmonary tuberculosis with respiratory super-infection pathogen.

Infection by this gram-negative bacillus as a causative agent of spontaneous bacterial peritonitis is described,<sup>12</sup> in addition to the case of a brain abscess by this microorganism that required surgical treatment.<sup>4</sup>

*Fica* and collaborators<sup>12</sup> described three individuals with infections associated with *H. alvei* isolation at different anatomical sites. In two cases it was recovered from blood cultures in subjects affected by a non-specific inflammatory lung nodule and pancreatic cancer, respectively. In a third case this agent was isolated from tracheal secretion in one admitted by a complicated skull trauma.

*Heras*<sup>3</sup> shows sepsis in a woman with renal transplantation, under the circumstances of chronic renal failure due to hepatorenal polycystic disease, chronic C-virus liver disease and immunosuppression. *Moreno*<sup>5</sup> describes an intrahospital outbreak of four children with bacteremia in a pediatric cardio-surgical unit.

In most of the described cases, infections by this pathogen have been associated with different predisposing factors, such as immunosuppression, pediatric ages or some antecedent of underlying chronic diseases with or without affection of the general state. The present report shows a case of infective endocarditis in a native mitral valve by *Hafnia alvei* in an apparently healthy one, whose clinical presentation and the causal germ is considered as atypical.

## ACKNOWLEDGMENTS

To Aida Jiménez Bosco and Reinaldo Peña Santana for the revision of the article. Angélica Gálvez, a medical student of third year, for her help.

## BIBLIOGRAPHIC REFERENCES

1. Moreno Moreno C. *Hafnia alvei*. Rev Chilena Infectol [Internet]. 2009 Ago [citado 21 jun 2017];26(4):355. Disponible en: [http://www.scielo.cl/scielo.php?script=sci\\_arttext&pid=S0716-10182009000500009](http://www.scielo.cl/scielo.php?script=sci_arttext&pid=S0716-10182009000500009)
2. Redondo J, Maseda E, Riquelme A, Alday E, Uña R, Criado A. *Hafnia alvei*: una causa infrecuente de neumonía grave en la Unidad de Reanimación. Rev Esp Anestesiol Reanim [Internet]. 2005 jun [citado 21 jun 2017];52(6):359-62. Disponible en: <https://www.sedar.es/images/stories/documentos/fondosredar/volumen52/n6/cclin2.pdf>

3. Heras M, Sánchez R, Fernández Reyes MJ, Hernando S. Sepsis por *Hafnia alvei* en una paciente con trasplante renal. Nefrología (Madr.) [Internet]. 2008 [citado 21 jun 2017];28(4):470-1. Available from: <http://www.revistanefrologia.com/es-publicacion-nefrologia-articulo-sepsis-por-hafnia-alvei-una-paciente-con-trasplante-renal-X0211699508005516>
4. Rodríguez R, Naval G, de Toro M. Absceso cerebral por *Hafnia alvei* [Internet]. Galicia: Sociedad Gallega de Medicina Interna; 1999 [actualizado 11 mar 2002; citado 21 jun 2017]. Disponible en: <http://www.meiga.info/documento.asp?sec=359&id=545>
5. Moreno Moreno C, Troncoso VC, Coria HP, Ledermann DW, Valle MG, Nuñez FC, Araya RP, Fernández OJ, Fernández RA. Reporte de cuatro casos clínicos de bacteriemia por *Hafnia alvei* en una unidad cardio-quirúrgica pediátrica. Rev Chilena Infectol [Internet]. 2010 feb [citado 21 jun 2017];27(1):40-4. Disponible en: [http://www.scielo.cl/scielo.php?pid=S0716-10182010000100006&script=sci\\_arttext](http://www.scielo.cl/scielo.php?pid=S0716-10182010000100006&script=sci_arttext)
6. Millán Rodríguez MR, Muñoz Pérez MA, Meseguer Frutos MD, Cano Sánchez A, Román López Andreu F, Soriano Palao J. Neumonía nosocomial por *Hafnia alvei*. An Med Interna (Madrid) [Internet]. 2003 Nov [citado 23 Jun 2017];20(11):47-8. Disponible en: [http://scielo.isciii.es/scielo.php?script=sci\\_arttext&pid=S0212-71992003001100010](http://scielo.isciii.es/scielo.php?script=sci_arttext&pid=S0212-71992003001100010)
7. Miró Meda JM, Tornos Mas P. Endocarditis infecciosa. En: Farreras Valentí P, Rozman C. Medicina Interna. 17<sup>th</sup> ed. Barcelona: Elsevier España; 2012. p. 553-66.
8. Osoria Mengana Y. Endocarditis infecciosa. En: Diagnóstico y tratamiento en medicina interna. Vicente Peña E, Rodríguez Porto AL, Sánchez Zulueta E, Quintana López L, Riverón González JM, Ledo Grogués D, et al. La Habana: Editorial Ciencias Médicas; 2011. p. 195-203.
9. Fowler VG y Bayer AS. Infective Endocarditis. En: Goldman L, Schafer AI, editors. Goldman's Cecil medicine. 24<sup>th</sup> ed. Philadelphia: Elsevier Saunders; 2012. p. 464-72.
10. Biblioteca virtual en salud de Cuba. Revistas médicas cubanas [Internet]. La Habana: Infomed; 1 de marzo de 2001 [actualizado 11 ene 2016; citado 12 abr de 2017]. [aprox. 2 pantallas]. Disponible en: <http://www.bvs.sld.cu/revistas/>
11. Karchmer AW. Endocarditis infecciosa. En: Bonow RO, Mann DL, Zipes DP y Libby P, editores. Braunwald. Tratado de cardiología : Texto de medicina cardiovascular. 9th ed. Barcelona: Elsevier España; 2013. p. 1561-82.
12. Fica CA, Larrain PMA, Caorsi PB, Olivares CR, Cereceda BM. Infecciones oportunistas por *hafnia alvei*: descripción de tres casos y revisión de la literatura. Rev Chilena Infectol [Internet]. 1998 [citado 21 jun 2017];15(2):112-6. Disponible en: <http://bases.bireme.br/cgi-bin/wxislind.exe/iah/online/?IsisScript=iah/iah.xis&src=google&base=LILACS&lang=p&nextAction=lnk&exprSearch=245440&indexSearch=ID>.
13. Fernández Peláez JM, Vives Soto M, Marqueño Ortega H, Goig Abarca I. Peritonitis bacteriana espontánea por *Hafnia alvei*. Med Clin [Internet]. 2001 Ene

[citado 21 jun 2017];116(11):437. Disponible en: <http://www.elsevier.es/pt-revista-medicina-clinica-2-articulo-peritonitis-bacteriana-espontanea-por-hafnia-S002577530171857X>

14. Gallego Page JC, Sánchez G, Ortigosa FJ, Ugarte J. Endocarditis sobre válvula protésica mitral producida por *Hafnia alvei*. Med Clin (Barc). 1999;112:199.

15. Hidalgo Tenorio C, Pasquau Liaño J. Tuberculosis pulmonar bilateral y sobreinfección respiratoria por *Hafnia alvei*. An Med Interna (Madrid) [Internet]. 2002 Oct [citado 21 jun 2017];19(10):[aprox. 4 p.]. Disponible en: [http://scielo.isciii.es/scielo.php?script=sci\\_arttext&pid=S0212-71992002001000015](http://scielo.isciii.es/scielo.php?script=sci_arttext&pid=S0212-71992002001000015)

Recibido: 24 de agosto de 2017.

Aprobado: 21 de septiembre de 2017.

*Junior Vega Jiménez*. Hospital Militar "Dr. Mario Muñoz Monroy". Matanzas, Cuba.  
Correo electrónico: [juniorvj.mtz@infomed.sld.cu](mailto:juniorvj.mtz@infomed.sld.cu)